

# Chapter 14

## APHASIA I: CLINICAL AND ANATOMIC ISSUES

Michael P. Alexander

The clinical study of aphasia began in 1861 with the observations of Paul Broca.<sup>1</sup> Within 40 or 50 years, all of the basic clinical phenomena reviewed here had been described and many of the major flashpoints of clinical and theoretical disagreement had been identified. In the past 20 years, fresh interest has come to clinical aphasia research from two directions: modern neuroimaging and cognitive neurosciences. Together, they have additionally provided tools to carry out aphasia-related language experiments in normals. Furthermore, old questions such as cerebral laterality, the influence of handedness, the effects of gender and bilingualism on aphasia, and the mechanisms of recovery have been reexplored. Much of this chapter—which reviews the basic clinical features of aphasia—could have been written 20, 50, or even 100 years ago. In 1995, it is possible to consider this material with greater appreciation of the variability found in the basic syndromes, of their anatomic complexities, of the natural history of recovery, and (although here only briefly) of the cognitive and linguistic deficits that fundamentally underlie the classic syndromes. The chapters on neuroimaging and on cognitive analysis of aphasia should be read along with this chapter.

### CLINICAL SYNDROMES

The description of syndromes of aphasia arose out of much the same motivation as the identification of other clinical neurologic syndromes: the need

to identify clinically useful associations between specific clusters of signs and the likely anatomy of the lesion producing them. The most clinically transparent signs of aphasia have generally been taken to be independent signs of brain damage. Thus, syndromes have been constructed out of reduced language output as well as impaired comprehension, repetition, and naming. Disorders of written language have been divided into additional syndromes only as reading and writing have been impaired beyond spoken language impairments. Using three independent signs will generate eight syndromes, assuming naming to be impaired in all aphasics.

Although these syndromes have reasonable clinical validity, there are numerous limitations to this type of syndrome construction. First, the syndromes depend on a sign being normal or not, much as a hemiparesis is present or absent; but the complexity of impairments in comprehension and language production are less amenable to simple dichotomous judgments. Thus, distinctions come to depend on the statistical properties and structural assumptions of the test. Second, there is no certainty that signs all have the same pathophysiological mechanism in all patients. For comprehension at the sentence level, in particular, there may be several independent pathways to impairment.<sup>2</sup> Third, the syndromes are not stable even when the anatomy is. A patient with a temporoparietal stroke may have an initial Wernicke's aphasia, but, over weeks, language improves to reach the clinical diagnosis of conduction aphasia.<sup>3</sup> Does

one conclude that the behavioral-anatomic correlations are with Wernicke's or conduction aphasia? Can one be certain that there are two distinct syndromes if they blur into each other? Should one conclude that only the early-phase correlations hold, that all correlations have built in corollaries about recovery, or that both are true? Fourth, most syndromes are polytypic—that is, they are defined by several criteria.' What do we conclude if only some of (the criteria are met? Would this be a less severe syndrome? A subsyndrome? A different syndrome altogether?

Despite these limitations, the classic syndromes do have utility. They serve as a type of shorthand for clinical communications. If told that a patient has transcortical motor aphasia 2 weeks after a stroke, one would know approximately what to expect of language examinations, what the range of possible brain lesions would be, what the prognosis should be, and what some reasonable treatments might be. If inclined, one would even know what interesting cognitive neuroscience issues the patient might illuminate.

### Broca's Aphasia

In Broca's aphasia, language output is nonfluent—that is, it is reduced in phrase length and grammatical complexity. This reduction can range from no recognizable output or repeated meaningless utterances to short, truncated phrases using only the most meaning-laden words (nouns). There is usually considerable hesitation and delay in production. Speech quality is impaired. Articulation is poor (dysarthria). Melodic line is disrupted (dysprosody), partly due to dysarthria but often more than just secondary to it. Volume is usually reduced at first (hypophonia). With time, speech takes on hyperkinetic (dyslionic and spastic) qualities. Language comprehension is adequate although rarely normal. Response to word-recognition tasks, simple commands, and routine conversation is generally good. Response to multistep commands and complex syntactical requests is generally poor. Repetition is poor, although often better than speech. Relational words (function words—articles, conjunctions, modifiers, etc.)

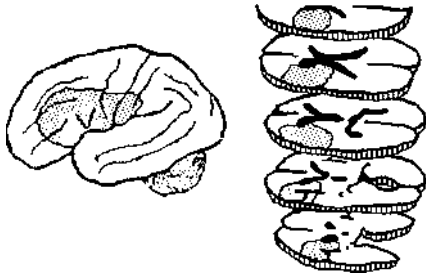
may be produced in repetition, but they are exceedingly uncommon in spontaneous speech. Written language parallels spoken, although some patients, while never regaining useful speech, develop writing that is telegraphic. Oral reading is usually agrammatic; so-called deep dyslexia (see Chap. 15) may emerge with this.<sup>5</sup> Naming is usually poor, but it may be surprisingly good in chronic patients. All types of errors can occur, although semantic errors are most typical for substantive words. Objects are frequently named better than are actions.<sup>7</sup>

Broca's aphasia is commonly accompanied by right hemiparesis, buccofacial apraxia, and ideomotor apraxia of the left arm (or both arms in the nonparetic case). Right-sided sensory loss and right visual field impairments (extinction and/or lower-quadrant deficit) are less frequent. Depression, frequently major, develops in approximately 40 percent of patients with Broca's aphasia."

Many patients have fractional syndromes of Broca's aphasia. Because all of these fractional disorders are still taxonomically closer to Broca's aphasia than to any of the other seven classic diagnoses, many aphasia systems will classify them all as Broca's aphasia." In analyzing reports of Broca's aphasia, it is crucial to understand the taxonomic rules of the report's assessment tool. If all fractional cases are considered Broca's aphasia, the anatomic correlations will seem imprecise. This is an example of the difficulty inherent in building syndromes with polytypic qualities. Analysis of the anatomic relationships within these fractional cases may be much more informative than lumping them all together on the basis of some overlap with the full syndrome.

### Chronic Broca's Aphasia

This syndrome, as described above, often emerges out of global aphasia." Damage can vary in extent; there does not seem to be a necessary and sufficient lesion profile. The most common pattern is extensive dorsolateral frontal, opercular, Rolandic, and anterolateral parietal cortical damage plus lateral striatal and extensive paraventricular

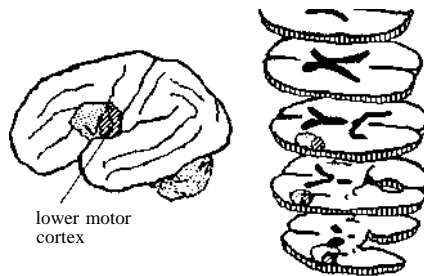


**Figure 14-1**  
Typical lesion associated with severe chronic Broca's aphasia.

ular white matter damage (Fig. 14-1)." Particularly critical to chronic Broca's aphasia is the subcortical extension of the lesion.<sup>12</sup> Long-lasting mutism can be seen after anterior deep lesions, undercutting supplementary motor area and cingulate-caudate projections.<sup>13</sup> Deep anterior periventricular white matter lesions disrupt dorsolateral frontal-caudate systems involved in ready access to complex output procedures.<sup>14</sup> They may also disrupt ascending anterior thalamic-frontal projections. Anterior-supraventricular-deep white matter lesions disrupt callosal frontal projections. Large periventricular and subcortical white matter lesions can disrupt all of the long parietotemporal to frontal projection pathways. All the distant corticocortical systems will be disrupted. A combination of these systems' disruptions seems to be the structural basis of persistent Broca's aphasia even with subcortical lesions only.

### Acute Broca's Aphasia

Infarctions or trauma that produce acute Broca's aphasia often involve the frontal operculum, lower motor cortex, lateral striatum, and subcortical white matter (Fig. 14-2).<sup>15</sup> These patients recover over weeks to months, with variable mixtures of initiation delay, syntactic simplification, paraphasias, speech impairment, and usually with impaired repetition.



**Figure 14-2**  
Lesion distributions of incomplete forms of Broca's aphasia. The entire lesion would produce "acute" Broca's aphasia. The anterior component involved alone (stippled area) would typically evolve toward transcortical motor aphasia. The posterior component involved alone would typically evolve toward aphemia. In either case, the residual aphasia would be mild.

### "Broca's Area" Lesion

Damage to the frontal operculum (areas 44 and 46) produces an acute aphasic disorder roughly compatible with Broca's aphasia (Fig. 14-2), but there is quite rapid improvement usually to transcortical motor aphasia or even just mild anomic aphasia.<sup>15</sup> Damage to the dorsolateral frontal cortex (areas 44, 46, 6, and 9) produces classic transcortical motor aphasia<sup>13</sup> (discussed in detail below). Damage to the subcortical frontal white matter or even to the dorsolateral caudate nuclei may produce the same deficit.<sup>16</sup> These observations suggest the existence of a "frontal-caudate" regional network required for construction of complex output procedures of language—syntax and narrative discourse at a minimum. Damage to this system is part of classic Broca's aphasia.

### Lower Motor Cortex Lesion

Damage to the lower 50 percent of the prerolandic gyrus can acutely produce a deficit pattern roughly compatible with mild Broca's aphasia, but there is rapid recovery to a much more limited

disorder of speech—predominantly of articulation and prosody—sometimes called aphemia (Fig. 14-2).<sup>10</sup> Damage to the subcortical outflow of lower motor cortex can produce the same speech deficit, suggesting the existence of a local (rolandic) network for articulation and some aspects of prosody that project to the brainstem. This, too, is part of classic Hroca's aphasia.

A rare variant of this restricted damage to motor systems of speech production is the foreign-accent syndrome.<sup>11</sup> A small number of cases have been described, usually emerging out of mild Broca's aphasia. In these patients, the predominant deficit is in speech prosody, but the quality of the prosodic deficit sounds to the listener like a foreign accent, not pathologic prosody. The reported lesions have all been in some component of the motor system for speech, either lower motor cortex<sup>12</sup> or pulamen or deep connections between lower motor cortex and basal ganglia.<sup>13</sup> The precise speech impairment has not been consistent, and the foreign accent syndrome probably represents a *heterogeneous group* with partial damage to the motor speech apparatus.

For all of these variants and fractional syndromes of Broca's aphasia, some improvement can be expected. The severe cases that often emerge from global aphasia typically have better recovery of comprehension than of speech; this recovery that may continue over a very long time.<sup>12</sup> Minimal recovery of spoken or written output from essentially none to classic telegraphic output is usually accompanied by lesion extent throughout the deep frontal white matter from the middle periventricular region to the region anterior and superior to the frontal horn.<sup>14</sup> The outcome of the milder cases is partly determined by lesion size,<sup>15</sup> but for these smaller lesions, precise lesion site seems to best account for evolution into the various fractional systems.<sup>16</sup> In both severe and milder cases, some patients may recover by reorganizing cerebral functions to allow some right-brain control of speech. Evidence for this comes from patients with serial frontal lesions<sup>17</sup> and from temporary inactivation of the right brain (Wada test) after left-brain stroke has produced severe nonfluent aphasia.<sup>18</sup>

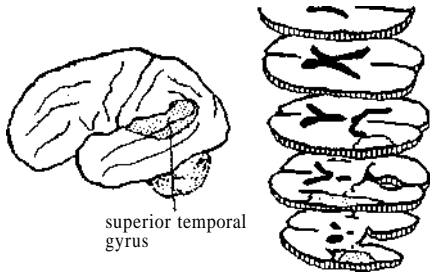
## Wernicke's Aphasia

In this disorder, language output is fluent—that is, normal in mean phrase length, generally sentence-length, and using all grammatical elements available in the language. Content may be extremely paraphasic<sup>19</sup> or empty. Paraphasic speech conforms to the general rules of the language but contains substitutions at the phonemic level (phonemic paraphasias such as "smoon" for spoon), the word level (semantic paraphasias such as "cup" for spoon), or entirely novel but phonologically legal words (neologisms such as "snopel"). Empty speech may consist of either vague circumlocutions or single words (thing, one, unit, it, going, etc.). Lengthy, complex, phonologically rich output with varied neologisms is jargonaphasia. Although statements may be of sentence length, grammar may become quite imprecise, usually because of semantic ambiguity; this is paragrammatism.<sup>20</sup> Speech is normal. Language comprehension is poor at the levels of word recognition, simple commands, and simple conversation. Repetition is very poor. Written language is comparable to spoken. Naming is very poor. Errors are paraphasias, circumlocutions, and nonresponses.

Apraxia to command is common, but when the patient is given a model to imitate, performance can be extremely variable, from persistently severe apraxia to normal performance.<sup>21</sup> Deficits in the right visual field are common. In the acute phase, patients may be anosognosic; but with awareness of deficits, agitation and suspiciousness may emerge.

Fractional syndromes of Wernicke's aphasia are less common but can occur. Some patients have relatively better auditory comprehension (and usually repetition); others have relatively better reading comprehension. Severe limb apraxia (both ideomotor, even with imitation of gestures, and ideational) is sometimes seen.

The minimal lesion producing Wernicke's aphasia is damage to the superior temporal gyrus back to the end of the sylvian fissure (Fig. 14-3).<sup>22</sup> If damage includes additional adjacent structures, either the deep temporal white matter or the supramarginal gyrus or both, problems will be more



**Figure 14-3**

*Typical lesion producing Wernicke's aphasia. Persistence and severity would depend on lesion extent (see text).*

persistent.<sup>25</sup> If damage includes middle and inferior temporal gyri, initial deficits will be more severe, anomia will be more persistent, and reading comprehension will be poor even if auditory comprehension improves. Patients with lesions restricted to the superior temporal gyrus may have predominantly auditory comprehension difficulties with relatively little anomia and much less reading impairment. The differential effects of lesion placement in the posterior temporal lobe certainly reflect variable damage to converging regional networks for several language processing systems. The auditory language system may be more specifically temporal, thus the relatively greater impairment of auditory comprehension. Visual language processing surely emerges out of the more posterior temporooccipitoparietal association cortex.\* Cross-modal lexical and semantic knowledge emerges out of a broad range of regions in the posterior association cortex, but available evidence highlights the inferior temporal and middle temporal/angular gyrus transition as the particularly key regions for word retrieval.\*

Severe and persistent Wernicke's aphasia seems to require damage to all of these regions or to their deep functional connections. The mechanisms of recovery are not completely known. As noted above, the brain regions involved in lexical-semantic (*unction*) are broadly distributed in posterior association cortex. Size of lesion in these re-

gions, extent of involvement of the superior temporal gyrus,<sup>27</sup> and extent of coincident damage to supramarginal and angular gyri<sup>28</sup> have all been implicated as factors in recovery of comprehension. Studies with positron emission tomography (PET) have demonstrated a variety of effects related to recovery. Heiss and colleagues, studying subacute recovery in a mixed group of aphasic syndromes, demonstrated that recovery of comprehension was proportional to recovery of resting blood flow in the surviving (left hemisphere, particularly the temporo-parietal junction.<sup>11</sup> Weiller and coworkers demonstrated that recovery in Wernicke's aphasia is closely related to a shift in PET activation to semantic tasks from left temporal in normals to right temporal in Wernicke's aphasics who recover." The precise meaning of these related studies is not known, but they all converge on the importance of posterior association cortex, either left or, if it is too damaged, right for recovery of comprehension.

Pure word deafness is sometimes considered a separate syndrome reflecting exclusive impairment to the auditory language processing system." Most patients are only relatively "pure," emerging out of Wernicke's aphasia with relatively better recovery of reading comprehension for anatomically specific reasons proposed above. Some patients have had only small left temporal lesions;<sup>1</sup> others have had bilateral temporal lesions." Depending upon the relative size and location of the bilateral lesions, these patients may be effectively deaf" (cortical deafness: bilateral Heschl gyrus lesions) or have agnosia for the meaning of all sounds (machinery, animals, musical instruments, etc.) even though they hear them (auditory environmental agnosia: large right lesion, whatever the left lesion<sup>14</sup>). Also, depending on specific lesion sites, language output can be variably abnormal, although to be "pure," it should be normal. In this case, the implication is that underlying knowledge of word phonology is preserved because spontaneous production is normal. Depending on lesion site, "relatively pure" cases may have considerable phonemic paraphasia or anomia.

The mechanism of pure word deafness is presumably damage to a system that converts the

acoustic signal into a phonologically meaningful stimulus." This is necessary but not sufficient for comprehension; for example, normals can repeat sentences in languages phonologically similar to their native one without understanding anything. There must still be merger of the processed acoustic signal with a semantic system. In some patients with Wernicke's aphasia, the phonological process seems very impaired; in others, the mapping to semantics and in yet others both are impaired.

### Conduction Aphasia

In conduction aphasia, language output is fluent. Content is paraphasic, usually predominantly phonemic.<sup>6</sup> There may be frequent hesitations and attempts to correct ongoing phonemic errors (so-called *conduit d'approche*). Speech is normal. Language comprehension is good except for auditory span. Repetition is poor, not always worse than spontaneous output but dominated by phonemic paraphasias on substantive words, particularly phonologically complex target words ("happy hippopotamus") or words embedded in phonologically complex sentences ("Dogs chase but rarely catch clever cats"). Written language is extremely variable in this syndrome. Writing is rarely better than speech, but it can be much more impaired. Oral reading is usually comparable to speech but can be better or worse. Reading comprehension is usually comparable to auditory but can be worse. Patients with the agraphia with alexia syndrome usually have conduction aphasia. Naming is also extremely variable, from extremely poor to nearly normal. Errors are paraphasias (phonemic especially).

Limb ideomotor apraxia is common initially but clears in most patients.<sup>24</sup> Right-sided sensory • loss or visual field impairment (extinction and/or lower quadrant deficit) are common.

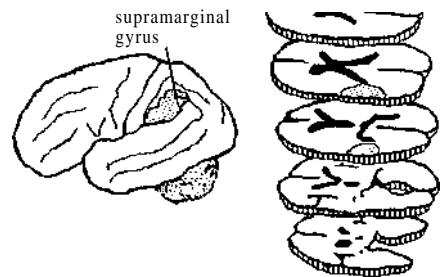
Most patients with conduction aphasia have prominently reduced auditory verbal short-term memory (STM), tested as digit-span, word-span, or sentence-length effect in repetition. There is, however, little specificity of the STM problem, as many patients with perisylvian aphasias have a similar problem. The STM deficit also has little

relevance to the language production problem, as similar output occurs in spontaneous output, oral reading and naming, as well as repetition. There is converging evidence that the inferior parietal lobule, particularly the supramarginal gyrus, is critical for all aspects of phonologic processing. Thus, lesions there have been blamed for pure STM deficits,<sup>35</sup> phonologic agraphia,<sup>3,37</sup> and phonologic alexia, all of which commonly emerge from conduction aphasia.

The necessary and sufficient lesion to produce conduction aphasia is damage to supramarginal gyrus<sup>38</sup> (Fig. 14-4). The classic correlation was with the arcuate fasciculus, putatively connecting temporal lobe to frontal lobe.<sup>39</sup> Lesions in subcortical parietal white matter disrupt this fasciculus and may represent the classic correlation.<sup>40</sup> Lesions in white matter deep to sensory cortex or in the subinsular extreme capsule as well as supramarginal cortex lesions may also produce conduction aphasia.<sup>41</sup> These observations suggest that temporoparietal short association pathways (i.e., a regional network) may support the phonologic output structure of speech. This network is required for phonologic accuracy in spontaneous output, repetition, oral reading, and naming. If disturbed phonologic structure of output is the hallmark of conduction aphasia, this would be the criterion structural basis.

Some patients have very extensive parietal

Figure 14-4  
Typical lesion producing conduction aphasia. Smaller lesions within this region may also produce similar aphasia (see text).



lesions with more severe anomia, agraphia, and limb ideomotor apraxia. Partial involvement of the superior temporal gyrus can produce initial Wernicke's aphasia that evolves into conduction aphasia with *very* paraphasic output and severe anomia. Again, the overlap of syndromes should be evident. Patients whose perisylvian arterial architecture just happens to catch the superior temporal lobe in a predominantly parietal stroke will have elements of pure word deafness (decreased auditory comprehension) with conduction aphasia (phonemic paraphasias, anomia, and agraphia). That combination would be indistinguishable from Wernicke's aphasia; in fact, it probably is Wernicke's aphasia except that recovery of comprehension would be "surprisingly" good.

Most patients with acute conduction aphasia have good recovery over a few weeks, although residual writing impairments, mild anomia, and occasional phonemic errors can be observed. For the more severe cases with marked anomia and very paraphasic output, recovery is less complete. The combination of significant phonologic and semantic deficits despite good comprehension can be very long-lasting. Over time, patients become less neologistic and more empty and circumlocutory, even if the basic deficits do not improve.<sup>42</sup>

### Global Aphasia

In many ways global aphasia is the easiest syndrome to define. By definition, patients have significant impairments in all aspects of language. Language output is severely limited—there is no more than "yes," "no," and a recurring stereotypic utterance ("da, da," "no way, no way," etc.). In some global aphasics (and Broca aphasics) the recurring utterance may be repeated rapidly in a richly inflected manner that suggests fluent output if only it could be comprehended. This is not jargonaphasia; it has none of the phonological richness or preservation of grammatical infrastructure of jargonaphasia. The mechanism of this richly inflected stereotype is unknown, and it has no known prognostic significance.

Comprehension is very impaired. The Boston Diagnostic Aphasia Examination (BDAAE)

definition allows comprehension up to the 30th percentile for an aphasic population.<sup>44</sup> This is compatible with considerable single-word comprehension. The language comprehension tasks most likely to be preserved in global aphasia are pointing to a named location on a map,<sup>45</sup> pointing to personally highly familiar names from multiple choice or acknowledging them when they are presented auditorily, and a small subset of commands ("take off your glasses," "close your eyes," "stand up").<sup>24</sup> Some global aphasics can do those tasks but little else. There is no repetition, naming, or writing.

Buccofacial and limb apraxia, to command and imitation, are nearly universal.<sup>24</sup> Right hemiplegia, hemisensory loss, and visual field impairments are all common but not invariable.

The most typical lesion involves or substantially undercuts the entire perisylvian region. At least, this would require a combination of the Broca's and Wernicke's aphasia lesions, but much clinical variability is seen. Some patients with Broca's aphasia lesions present as global aphasics without evident temporal lesions.<sup>46,47</sup> Conversely, some patients with very extensive posterior lesions that extend into subrolandic white matter present with global aphasia without *any* definite frontal or even anterior periventricular lesion. The mechanism of severe comprehension loss without a temporal lesion in a substantial fraction of global aphasics, is not known. The same effect is not seen without coincident frontal lesions—that is, even enormous cortical and subcortical parietal lesions alone do not cause such deficits in comprehension. The coincident frontal lesion may produce additional cognitive problems—such as inattention, underactivation, unconcern, poor problem solving (particularly relevant when the Token Test is the defining tool of comprehension), or perseveration—that interact with more modest phonologic/semantic deficits to produce more profound functional comprehension deficits. Alexander and associates have suggested that a sufficiently great lesion of the deep temporal white matter might undercut connections to the temporal lobe.<sup>48</sup> Naeser and colleagues found these deep temporal lesions to be associated with poor comprehension

in many global aphasics.<sup>21</sup> There was good recovery of comprehension in cases with deep temporal lesions but intact temporal cortex. Heisse and co-workers have demonstrated a very high correlation between reduced leptomeningeal blood flow in resting IET and poor comprehension, whatever the anatomic limits of the infarction.<sup>19</sup> Vignolo and associates<sup>46</sup> and DC Kcn/i and colleagues,<sup>47</sup> who have provided the most meticulous description of global aphasia without temporal lesions, have not found that temporal white matter lesions easily account for the deficits in comprehension.

Some patients with global aphasia have no hemiparesis. As a group, they are likely to have only a large frontal lesion or separate frontal and temporal lesions.<sup>48</sup> The purely frontal lesions are again presumably causing a quasicomprehension deficit due to inattention, activation, perseveration, and so on. These patients are also likely to have a better prognosis, but absence of hemiparesis is not a guarantee of a good outcome, as the absence of hemiparesis only means that a small portion of paraventricular white matter has been spared.<sup>50</sup>

When caused by infarction, global aphasia has a poor prognosis. Smaller lesions (some without hemiparesis) will improve quickly. After infarction, patients still meeting taxonomic criteria for global aphasia at 1 month postonset have a very low probability of improving substantially.<sup>3</sup> Large hemorrhages may be associated with more late recovery, but by 2 months without improvement, the prognosis remains grim. Many patients show gradually improving comprehension over weeks and months and eventually reach taxonomic criteria for severe Broca's aphasia.

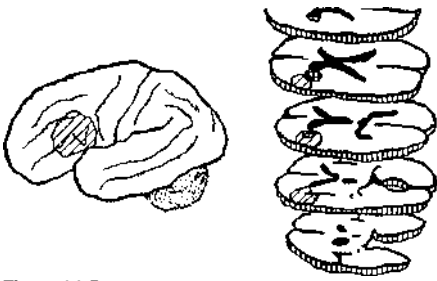
### Transcortical Motor Aphasia

In this syndrome, language output is commonly viewed as nonfluent because there is substantial initiation block, reduction in average phrase length, and simplification of grammatical form.<sup>49</sup> Many patients with transcortical motor aphasia (TCMA) are initially mute and may remain mute or nearly so for days or weeks. Note that, if they are mute, repetition is obviously absent and, by

strict taxonomic criteria, such patients would initially be called Broca's aphasics. Frank agrammatism is uncommon; responses are simply terse and delayed. Echolalia in various forms is frequently observed. Completely uninhibited echolalia is unusual, but fragmentary echoing, particularly of commands, may be observed. Incorporation echolalia is more common. The patient incorporates a portion of a question into the initial portion of his response. Speech quality is normal in the classic case. Repetition is, by definition, normal or at least vastly superior to spontaneous output. Recitation of even very complex overlearned material (e.g., *The Lord's Prayer*) may be flawless. Language comprehension is supposed to be normal, but, as observed above, the large frontal lesions most often associated with TCMA may produce substantial impairment of comprehension. Writing is usually similar to spoken output, but patients rarely write to dictation as well as they repeat. Reading comprehension parallels auditory. Oral reading may be quite normal if initial prompts are provided. Naming is quite variable; errors are nonresponses, semantic paraphasias, or perseverations.\*

Transcortical motor aphasia may have any range of associated motor deficits, depending upon lesion site. The classic case has no motor deficit. Hemiparesis accompanies many cases of subcortical TCMA.<sup>14</sup> Inverted hemiparesis (leg worse than arm) and a contralateral grasp reflex accompany medial frontal TCMA.<sup>51</sup> Sensory loss and visual field deficits are not usually seen except in subcortical cases. Buccofacial apraxia may be seen, but limb ideomotor apraxia is less common.<sup>52</sup>

The classic patient has a large dorsolateral frontal lesion, typically extending into the deep frontal white matter (Fig. 14-5).<sup>53</sup> Identical cases have been reported with just a white matter lesion abutting the frontal horn of the lateral ventricle.<sup>48</sup> Very similar cases involve the capsulostriatal region, particularly the dorsolateral caudate and adjacent paraventricular white matter (Fig. 14-6).<sup>54</sup> The similarity of the aphasia associated with these disparate lesions is paralleled by the nearly identical reduction in blood flow seen on resting PET or single photon emission computed tomography (SPECT) in dorsolateral frontal cortex, whatever

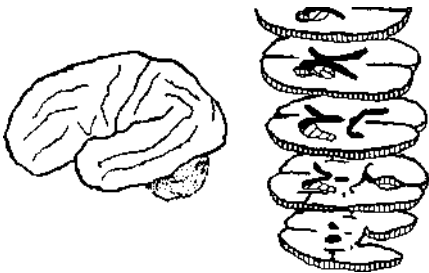


**Figure 14-5**  
Typical lesions producing transcortical motor aphasia. Note overlap with Broca's area lesions (Fig. 14-2).

(he lesion site.<sup>5,5,57</sup> The more posteriorly the lesion extends along the paraventricular white matter, the likelier the presence of dysarthria (see discussion of aphemia, above) and hemiparesis. Damage to the medial frontal lobe, particularly the supplementary motor area, produces TCMA-like disturbance." Mutism may be more prolonged. When patients begin to speak, they rarely show any frankly aphasic qualities. They simply do not speak much.

Analysis of cortical and subcortical cases

**Figure 14-6**  
Large lenticulostriate lesion, which is often associated with transcortical motor aphasia, frequently accompanied by speech disturbance and hemiparesis. Smaller lesion (cross-hatched area) may produce mild transcortical motor aphasia without motor deficits.



with TCMA suggests that one fundamental deficit is in generative language tasks.<sup>14-54</sup> The patients seem to have very limited capacity to generate complex syntax. They may reuse the syntax in a question they are asked (incorporation echolalia). They may produce short responses, even short sentences, quite well. When asked an open-ended question, however, they do not have timely access to the range of syntax needed to answer.<sup>54n</sup> Bed-side generative tasks—word-list generation, storytelling, or producing sentences using provided main verbs—will be impaired out of proportion to other language tasks. Patients with large dorso-lateral frontal lesions may have little or no aphasia on standard tests but still be unable to tell a story or recite a narrative in normal fashion.

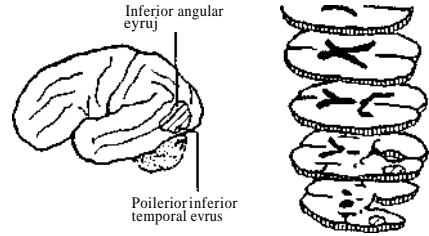
A second fundamental deficit in TCMA is reduction in activation to speak (or to write). Analysis of lesion site effects, particularly the profound mutism that occurs with medial frontal damage, suggests that reduced activation is due to loss of ascending dopaminergic pathways. The medial frontal regions are primary targets of the nonnigral dopaminergic system.<sup>5\*</sup> Bilateral damage to this system anywhere from the upper mid-brain to the frontal cortex results in akinetic mutism,<sup>57</sup> evolving into less flagrant forms often called abulia.<sup>58</sup> Transcortical motor aphasia may represent a subsyndrome of akinetic mutism with more rapid clearing of mutism and less global akinesia because the lesion is only unilateral. The improvement in fluency and speech rate after administration of direct dopamine agonists supports this proposition.<sup>6n</sup> Improvement with bromocriptine is almost uniquely seen in TCMA.

### Transcortical Sensory Aphasia

In transcortical sensory aphasia (TCSA), language output is fluent. Content is very empty, with semantic paraphasia predominating. All patients make abundant use of one-word circumlocutions and nonspecific filler words, such as *one*, *things*, *docs*, etc. Phonemic paraphasias and neologistic jargon are less common, so that output is more accurately described as extended English jargon. Content is also often perseverative. Speech

quality is normal. Repetition is, by definition, normal. Language comprehension is impaired. In particular, single-word comprehension may be quite poor. When accompanied by accurate repetition of the test words and even their incorporation in sentences. ("A watch? I should know that. Is one of these a watch?"), the behavior has been called alienation of word meaning." There may be category-specific comprehension impairments with particularly good performance at following commanded actions and very poor performance at pointing to named targets. Many patients will accept incorrect names or quibble over accuracy. ("You could call it a watch, but I don't think it is one.") Naming is poor, and again some category-specificity may be observed. Some patients are worse at naming animals, insects, and other animate objects than tools and other inanimate objects.<sup>62</sup> There is no important discrepancy between naming performance to different sensory modalities. Many patients respond quickly to phonemic cues but will then reject or be uncertain about the correct response. This behavior has been called a two-way naming impairment.<sup>11</sup> Written output may be similar to spoken, but patients usually do not write extensively and are very perseverative. Reading aloud and reading comprehension are both abnormal. In many patients reading comprehension is even worse than auditory comprehension.

Transcortical sensory aphasia has been described after lesions in middle and inferior temporal gyri (Fig. 14-7).<sup>61</sup> The temporal lesion may produce a right visual field defect if white matter extent reaches the geniculocalcarine pathways. Many cases of TCSA have unexpected lesion sites involving the entire perisylvian cortex, a lesion much likelier to produce global aphasia." The mechanism for this is unknown, although some variant on bilateral language representation is usually recruited. Some cases with temporal lesions may also involve the inferior temporooccipital region—for instance, after posterior cerebral artery infarction. These patients will certainly have very impaired reading.<sup>2\*</sup> Many have associative agnosia.<sup>65</sup> Not only can they not name an object or point to a named object but they cannot



**Figure 14-7**

*Typical lesion producing transcortical sensory aphasia. Lesions more medial and inferior, usually posterior cerebral artery infarctions, may produce similar aphasia (see text).*

indicate its use or sort it into a correct functional category (i.e., put a pencil with chalk rather than with a knife). Thus, the deficit is not restricted to *lexical* semantic knowledge but involves actual semantic knowledge. This may be modality-specific, with visually presented tasks more impaired,<sup>15</sup> or it may affect all modalities equally."

Transcortical sensory aphasia is almost monotypic in that it is fundamentally a disorder of semantic processing. Nevertheless, different aspects of semantic knowledge and access to semantic knowledge may be impaired in different cases. The inability of patients with TCSA to associate a name with an object is the result of a semantic disorder at the interface between language and semantic memory. When semantic memory is more globally affected, patients are unable to demonstrate recognition of objects by nonverbal means as well (see Chap. 23). This is most commonly seen in degenerative diseases with a predilection for temporal cortex, such as Alzheimer Disease, Pick Disease, and so-called Semantic Dementia.<sup>21, 22, 27, 100</sup>

### **Anomic Aphasia**

Anomic aphasia is a much less homogeneous grouping than any of the other classic syndromes. By definition, language is fluent, comprehension good, and repetition good. The only deficit in spo-

ken language is in word retrieval. Paraphasias are infrequent. Word-finding problems usually produce filler words' or circumlocutions. Other impairments vary with lesion site.

Anomic aphasia is the residual state of many aphasic disorders after time for improvement.<sup>21</sup> As a primary diagnosis, anomic aphasia usually accompanies lesions in the same regions as TCMA or TCSA.<sup>100</sup>

As noted, most patients with TCMA are or at least become basically fluent but with terse, unelaborated utterances. When it is accompanied by word-finding deficits, this condition would qualify as anomic aphasia. Anomic aphasia is also the mildest form of TCSA, representing a deficit only in lexical retrieval from semantic stores. Thus, when anomic aphasia is caused by a dorsolateral frontal lesion, there are no accompanying neurologic signs. When it is caused by a deep frontostriatal lesion, there may be dysarthria, hemiparesis, and buccofacial apraxia, depending upon lesion extent. When it is caused by a posterior association cortex lesion, there may be a visual field deficit and alexia, depending upon lesion extent. When anomic aphasia is the residual of partly recovered conduction or Broca's aphasia, the accompanying signs are as expected for those disorders.

### Mixed Transcortical Aphasia

In mixed transcortical aphasia (MTA), language output is nonfluent. Comprehension is impaired. Naming is poor. Repetition is preserved. Echolalia and fragmentary sentence starters ("I don't ..., "Not with the ...") are common. Speech quality is normal. Writing and reading are similarly reduced.

In the patient whose case report defined this syndrome, MTA was due to bilateral hypoxic neuronal loss in the arterial border zones,<sup>TM</sup> but ischemic damage in the left border zones could presumably cause the same disorder. The implication is that MTA requires a combination of the lesions of TCMA and TCSA, with perisylvian structures allowing repetition preserved. Most cases are actually due to large frontal lesions in the region of

TCMA lesions. The comprehension defect is probably due to a mixture of frontal impairments, exactly as described for restricted frontal lesions and global aphasia. Comprehension improves, and patients evolve toward TCMA. Associated lesions are as described for TCMA.

Large anterior thalamic lesions also produce MTA.<sup>71-73</sup> Most cases have involved the anterior, ventrolateral, and dorsomedian nuclei at a minimum.<sup>72</sup> Damage to those three nuclei effectively deprives the frontal lobe of thalamic input and modulation. Patients are often mute initially. When they speak, the reduction in narrative and terseness of structure are similar to those of TCMA. The impairment in comprehension may be due to the speculative "frontal" mechanisms. The associated signs depend upon lesion extent out of the thalamus. Recovery of language is usually good.

### CROSSED APHASIA AND APHASIA IN LEFT-HANDERS

The foregoing review is valid for most right-handers with lesions of the left hemisphere. For the 10 percent of the population that is left-handed and for the approximately 2 to 5 percent of the right-handed population that becomes aphasic after a right-brain lesion (crossed aphasia), some modifications of the clinical rules are required. For left-handers, the phenomenology of aphasia is complicated by the very issue of left-handedness. More than right-handers, all left-handers are not created equal; they vary greatly in degree and nature of hemispheric specialization for language. For both populations the phenomenology is further complicated by irregularities in lateral dominance for other typically lateralized functions, such as praxis and some aspects of visuospatial function. Only a brief summary of these issues is possible here.

### Crossed Aphasia

The incidence of crossed aphasia has been reported as anywhere from 1 to 13 percent.<sup>74,76</sup> The

stroke population" is least contaminated by possible bilateral lesions, but in all populations methodological limitations (defining handedness and aphasia testing strategies) leave the actual incidence uncertain. A reasonable estimate is 2 to 5 percent.

Patients with crossed aphasia fall into two broad categories. About 70 percent have a standard aphasia syndrome associated with, at least approximately, the lesion site expected in the left hemisphere." All types of aphasia profiles can occur with the expected lesions (albeit in the right hemisphere). The other 30 percent have striking anomalies in the aphasia-lesion relationship." In this group, unexpectedly mild aphasia syndromes occur despite large lesions that would typically cause a more severe aphasia. Conduction aphasia or phonologic agraphia have been seen despite large perisylvian lesions.<sup>77\*</sup> In other patients with large perisylvian lesions, transcortical sensory aphasia or anomic aphasia has been described."<sup>\*1</sup> Alexander and Annett have suggested that these anomalous cases point to possible discrepant lateralizations of phonologic and semantic functions.<sup>71</sup> Patients with crossed aphasia may have a better capacity for recovery.

Lateralization of praxis and visuospatial functions in crossed aphasia has not been as definitely addressed as the language functions. Castro-Caldos and coworkers claim that these functions show anomalous lateralization less frequently than language, asserting that praxis remains in the left hemisphere contralateral to the preferred right hand and that visuospatial functions remain in the right hemisphere.<sup>74</sup> Others have disputed this, arguing from case reports that all functions show a high rate of anomalous lateralization.<sup>\*2</sup> Alexander and coworkers have reviewed the case reports of anomalous visuospatial lateralization to the left hemisphere in right-handers." They have proposed that there is a subset of right-handers who have chance lateralization of all functions. These authors, among others, have even proposed that a genetic basis for the inheritance of handedness and laterality of cognitive functions such as the right shift theory of Annett<sup>777</sup>" can

account for the rates of all anomalies. The biological basis of crossed aphasia, however, remains unknown.

### Aphasia in Left-Handers

Left-handers make up 10 percent of the population, but they are a much more heterogeneous group than right-handers. If a strict criterion for left-handedness is used, most of the left-handed population becomes relabeled as being mixed-handed.<sup>76</sup> Thus, some authorities simply refer to non-right-handers. The rate of cerebral lateralization of left-handers depends to some extent on the criteria used to define the group. Large studies of left-handed aphasics have been reasonably consistent, however, in finding that about 70 percent have left-brain lesions and 30 percent have right-brain lesions." Hecaen has computed that approximately 15 percent probably would be aphasic after a lesion of either hemisphere; that is, they have bilateral language representation. Whether aphasic after left or right brain lesions, the proportion of cases with anomalous aphasia-lesion relationships is higher than in right-handers.<sup>\*1</sup> It has been claimed that left-handers have better recovery than right-handers,<sup>112</sup> but, as with crossed aphasia, this question is muddled by the higher proportion of mild aphasics.<sup>\*1</sup> It is also unclear if better recovery means bilateral language capacity so all functions have higher potential for recovery or divergent lateralization of functions so that some are left uninvolved by any lateralized lesion."<sup>77m</sup> Both factors are probably operative, but in different patients.

Lateralization of praxis and visuospatial function shows anomalies at a rate similar to those of crossed aphasia. Every possible arrangement of impaired and preserved functions has been reported after left or right lesions." Since the biological basis of neither handedness nor the lateralization of cognitive functions has been established, it remains an open question how these anomalies occur in left-handers as well as right-handers.

## EFFECT OF ETIOLOGY

### Infarctions

Almost all of the foregoing is based on the literature accumulated from strokes. Infarcts have numerous advantages for clinicoanatomic correlations. They are sudden in onset, and there is therefore no accommodation and compensation prior to clinical presentation. Boundaries between damaged and nondamaged brain are fairly precise, so correlations are clearer. Nevertheless, the vascular system cannot provide every topographic variation of brain injury; therefore much of what has come to us as classic syndromes could easily be partially artifactual correlations produced by the limited independence of lesions sites from infarctions.

There are some aphasic syndromes that are commonly believed to be caused by emboli because the distribution of infarction seems most plausibly to be in the territory of a branch of the middle cerebral artery. The fractional Broca's aphasias, conduction aphasia, and Wernicke's aphasia all seem likely to have an embolic basis when due to infarction. Global aphasia and Broca's aphasia require more extensive damage in the territory of the middle cerebral artery. There is, however, no basis for presuming an infarction mechanism simply on the basis of these aphasia types.

### Hemorrhages

All of the rules established for infarctions apply for hemorrhages if the hemorrhage happens to be in the same brain topography as an infarction pattern. Patients with hemorrhages may be much more impaired initially because of physiologic deficits not primarily related to aphasia—mass effects, intraventricular blood, and so on. Hemorrhages are not constrained by vascular patterns, so entirely novel arrangements of lesions can be seen. This may be exemplified most clearly with lesions of the lenticulostriate region. Infarctions tend to be partially or completely limited to the middle cerebral artery perforators, but hemorrhages can dissect out of that limited region. Much

of the variability reported after lenticulostriate lesions<sup>\*5</sup> may be due to idiosyncratic extensions of hemorrhages.<sup>\*6</sup>

### Trauma

Focal contusions can occur anywhere, depending upon the direction of the blow, skull fragments, and so forth. When the contusion is in a perisylvian region, the resulting aphasia will usually follow the rules established by infarctions. Conduction and Wernicke's aphasias may be seen with predominantly superficial lesions and so may be quite typical. Cortical contusions rarely cause injury deep enough to damage all of the required deep structures (see above) and thus to produce nonfluent aphasia. There is a strong tendency for traumatic contusions to arise from basal structures due to inertial effects. Focal contusions of the inferior temporal lobe will cause anomic aphasia. If the lesions are large and extend into lateral temporal lobe or hemorrhage dissects up into the deep temporal white matter, patients may present with Wernicke's aphasia or TCSA. Trauma can also cause large epidural or subdural hematomas that do not directly affect language zones. They cause cerebral herniation with entrapment of the posterior cerebral artery, causing occipitotemporal infarctions with alexia and anomia. This herniation-caused infarction can be superimposed on direct temporal contusion, resulting in a very severe fluent aphasia.

### Tumors

The lesson for aphasia is no different than that for any cognitive function. In general, large tumors produce relatively much less cognitive impairment than an infarction of the same size would produce, but tumors produce symptoms qualitatively appropriate for the region involved. Tumors tend to infiltrate and gradually disrupt function, allowing substantial compensation as the disorder progresses. The conformity with patterns established by infarctions will be correlated largely with the malignancy and speed of growth of the tumor.

## Herpes Simplex Encephalitis

Although rare, herpes simplex encephalitis (HSE) has a predilection for the medial temporal lobes, basal-medial frontal lobes, and insular cortices. Survivors of HSE frequently have severe amnesia.<sup>12,17</sup> Patients with extensive left-sided HSE lesions, including the inferotemporal lobe, commonly show category-specific semantic deficits.<sup>62-67</sup>

## Dementia

The most common dementing illnesses—DAT and multi-infarct dementia (MID)—both cause language impairments. Dementia of the Alzheimer type typically presents with memory and language disturbances.<sup>18</sup> The language problem begins as anomia and is often misidentified by families as memory impairment. With time, the language disorder evolves toward TCSA, and the patients' semantic memory erodes.<sup>19</sup> The structure of this erosion is fairly predictable. Highly typical semantic associations survive longer than the semantic associations and attributes of low typicality.\* For instance, the patients may still recognize the words and concepts behind "cat," but not the words and then even the concepts of "leopard," "fang," or "litter." It has been proposed that this slow erosion of semantic knowledge—first words and (then) concepts—is the fundamental cognitive deficit of DAT.<sup>20</sup> Its presumed pathologic basis is the loss of neurons in posterior association cortex.

If one of the infarcts is in (the language /one, MID may cause aphasia directly. The more typical pathology of MID is, however, numerous small infarcts in subcortical regions. These lesions may produce a variety of motor speech impairments such as articulatory problems, hypophonia, dysprosody, and rale disturbances. A recognizable aphasic syndrome does not occur, but patients may show cognitive deficits similar to those seen with frontal lobe lesions, including disturbances in all aspects of generative language: reduced word-list generation, terse or unelaborate utterances, and poor narrative ability. It has been suggested

that a single small infarct in the genu of the left internal capsule is sufficient to disconnect frontal-thalamic circuitry and produce these deficits.<sup>19</sup>

A rarer form of degenerative dementia, primary progressive aphasia, is virtually restricted to language deficits.<sup>21</sup> The most common form is progressive loss of semantics and has therefore also been called semantic dementia<sup>19</sup> (see Chap. 23). The presentation is usually similar to the language impairments of DAT—anomia initially progressing to TCSA and finally to loss of semantic concepts and knowledge. Unlike DAT, other cognitive functions remain intact in these cases. Pathology is restricted to the anterior inferior temporal lobes, and the histopathology is usually Pick disease.<sup>22,23</sup> Nonfluent forms of primary progressive aphasia have also been described;<sup>24</sup> however, the pathology has not always been established.

## REFERENCES

1. Broca P: Perte de la parole. Ramollissement chronique et destruction partielle du lobe antérieur gauche du cerveau. *Bull Soc Anthropol* 2:235, 1861.
2. Goodglass H: *Understanding Aphasia*. San Diego, CA: Academic Press, 1983, pp 247-250.
3. Kertesz A, McCahc P: Recovery patterns and prognosis in aphasia. *Brain* KXU-18, 1977.
4. Caramazza A: The logic of neuropsychological research and the problem of patient classification in aphasia. *Brain Lang* 21:9-20, 1984.
5. Marshall JC, Newcombe F: Patterns of paralexia. *J Psycholing Res* 2:175-199, 1973.
6. Ardila A, Rosselli M: Language deviations in aphasia: A frequency analysis. *Brain Lang* 44:165-180, 1993.
7. Kohn SE: Verb finding in aphasia. *Cortex* 25:57-69, 1989.
8. Robinson RG, Kubos KL, Starr LB, et al: Mood disorders in stroke patients: Importance of location of lesion. *Brain* 107:81-93, 1984.
9. Mazzocchi F, Vignolo LA: Localisation of lesions in aphasia: Clinical-CT scan correlations in stroke patients. *Cortex* 15:627-654, 1979.
10. Mohr JP, Pessin MS, Finkelstein S, et al: Broca's aphasia: Pathologic and clinical. *Neurology* 28:311-324, 1978.

11. Naeser MA, Hayward RW: Lesion location in aphasia with cranial computed tomography and the Boston Diagnostic Aphasia Exam. *Neurology* 28: 545-551, 1978.
12. Naeser MA, Palumbo CL, Helm-Esland N, et al: Severe nonfluency in aphasia: Role of the medial subcallosal fasciculus and other white matter pathways in recovery of spontaneous speech. *Brain* 112:1-38, 1989.
13. Freedman M, Alexander MP, Naeser MA: Anatomic basis of transcortical motor aphasia. *Neurology* 34:409-417, 1984.
14. Mega MS, Alexander MP: Subcortical aphasia: The core profile of capsulostriatal infarction. *Neurology* 44:1824-1829, 1994.
15. Alexander MP, Naeser MA, Palumbo C: Broca's area aphasia. *Neurology* 40:353-362, 1991.
16. Schiffl HB, Alexander MP, Naeser MA, Galahurda AM: Aphemia: Clinical-anatomic correlations. *Anil New-ill* 4(1):720-727, 1983.
17. Monrad-Krohn OH: Dysprosody or altered "melody of language." *Brain* 70:405-415, 1947.
18. Blumstein SE, Alexander MP, Kyalls JH: The nature of (he foreign accent syndrome: A case study. *Brain Lang* 31:215-244, 1987.
19. Graft-Radford NR, Cooper WE, Colsher PL, Damasio AR: An unlearned foreign "accent" in a patient with aphasia. *Brain Lang* 28:86-94, 1986.
20. Prin RS, Snow E, Wagenaar E: Recovery from aphasia: Spontaneous speech versus language comprehension. *Brain Lang* 6:192-211, 1978.
21. Basso A, Gardelli M, Grassi MP, Mariotti M: The role of the right hemisphere in recovery from aphasia: Two case studies. *Cortex* 25:555-556, 1989.
22. Kinsbourne M: The minor hemisphere as a source of aphasic speech. *Tram A/n Nettrol Av.voc* 96:141-145, 1971.
23. Goodglass H: *Undemanding Aphasia*. San Diego, CA: Academic Press, 1983, pp 107-109.
24. Alexander MP, Baker E, Naeser MA, et al: Neuropsychological and neuroanatomical dimensions of ideomotor apraxia. *Brain* 118:87-107, 1992.
25. Naeser MA, Helm-Esland N, Haas G, et al: Relationship between lesion extent in Wernicke's area on computed tomographic scan and predicting recovery of comprehension in Wernicke's aphasia. *Anh Neural* 44:73-82, 1987.
26. Kertesz A, Lau WK, Polk M: The structural determinant of recovery in Wernicke's aphasia. *Brain Lang* 44:153-164, 1993.
27. Seines OA, Knopman DS, Niccum N, et al: Computed tomographic scan correlates of auditory comprehension deficits in aphasia: A prospective recovery study. *Ann Neural* 13:558-566, 1983.
28. Henderson VW, Friedman RB, Teng EL, Weiner JM: Left hemisphere pathways in reading: Inference from pure alexia without hemianopia. *Neurology* 35:962-968, 1985.
29. Damasio A: Synchronous activation in multiple cortical regions: A mechanism for recall. *Semin Neuosci* 2:287-290, 1991.
30. Heiss W, Kessler J, Karbe H, et al: Cerebral glucose metabolism as a predictor of recovery from aphasia in ischemic stroke. *Arch Neurol* 5(1):958-964, 1993.
31. Weiller C, Isensee C, Rijntjes M, et al: Recovery from Wernicke's aphasia: A positron emission tomography study. *Ann Neural* 37:723-732, 1995.
32. Takahashi N, Kawamura M, Shinolou H, et al: Pure word deafness due to left hemisphere damage. *Cortex* 28:295-303, 1992.
33. Auerbach S, Allard T, Naeser MA, et al: Pure word deafness: Analysis of a case with bilateral lesions and a defect at the prephonemic level. *Brain* 105:271-300, 1982.
34. Fujii T, Fukatsu R, Watabe S, et al: Auditory sound agnosia without aphasia following a right temporal lobe lesion. *Cortex* 26:263-268, 1990.
35. Paulesu E, Frith CD, Frackowiack RSJ: The neural correlates of the verbal component of working memory. *Nature* 362:342-345, 1993.
36. Roelgen DP, Sevush S, Heilman KM: Phonological agraphia: Writing by the lexical semantic route. *Neurology* 33:755-765, 1983.
37. Alexander MP, Friedman RB, Lovero F, Fischer RF: Lesion localization in phonological agraphia. *Brain Lang* 43:83-95, 1992.
38. Palumbo CL, Alexander MP, Naeser MA: CT scan lesion sites associated with conduction aphasia in Sc K (cd): *Conduction Aphasia*, (fillsdale NJ: Erlbaum, 1992, pp 51-75.
39. Benson DF, Shremata WA, Bouchard R, et al: Conduction aphasia: A clinicopathological study. *Arch Neurol* 28:339-346, 1973.
40. Mendez MF, Benson DF: Atypical conduction aphasia: A disconnection syndrome. *Arch Neurol* 42:886-891, 1985.
41. Damask H, Damasio AR: The anatomical basis of conduction aphasia. *Brain* 103:337-350, 1980.
42. Kertesz A, Benson DF: Neologistic jargon: A clinicopathological study. *Cortex* 3f:2-386, 1971.
43. Poeck K, de Bleser R, von Keyserlingk DO: Neuro-linguistic status and localization of lesions in

- aphasic patients with exclusively consonant vowel recurring utterances. *Brain* 107:199-217, 1984.
44. Goodglass H, Kaplan E: *The Assessment of Aphasia and Related Disorders*. Philadelphia: Lea & Febiger, 1983, p 97.
  45. Wapner W, Gardner H: A note on patterns of comprehension and recovery in global aphasia. *J Speech Hearing Res* 29:765-771, 1979.
  46. Vignolo LA, Boccardi E, Caverni L: Unexpected CT-scan finding in global aphasia. *Cortex* 22:55-69, 1986.
  47. DeRenzi K, Colombo A, Scarpa M: The aphasic isolate. *Brain* 114:1719-1730, 1991.
  48. Alexander MP, Naeser MA, Palumbo CL: Correlations of subcortical CT lesion sites and aphasia profiles. *Brain* 110:961-991, 1987.
  49. Tranel D, Biller J, Damasio H, et al: Global aphasia without hemiparesis. *Arch Neurol* 44:304-308, 1987.
  50. Legal! AD, Rubin AJ, Kaplan LR, et al: Global aphasia without hemiparesis. *Neurology* 37:201-205, 1987.
  51. Alexander MP: Speech and language deficits after subcortical lesions of the left hemisphere: a clinical, CT, and PET study, in Vallar G, Cappa SF, Walsch C-W (eds): *Neuropsychological Disorders Associated with Subcortical Lesions*. Oxford, England: Oxford Science Publications, 1991, pp 454-477.
  52. Demonet JF, Puel M: "Subcortical" aphasia: Some proposed pathophysiological mechanisms and their rCBF correlates revealed by *SPECT*. *J Neuroling* 6:319-344, 1991.
  53. Rubens AB: Transcortical motor aphasia. *Studies Neuroling* 1:293-306, 1976.
  54. Luria AR, Tsvetkova LS: Towards the mechanism of "dynamic aphasia." *Acta Neurol Psychiatr Belg* 67:1045-1067, 1967.
  55. Costello A de L, Warrington EK: Dynamic aphasia. *Cortex* 25:103-114, 1989.
  56. Lindvall O, Bjorklund A, Moore RY, Stenevi U: Mesencephalic dopamine neurons projecting to neocortex. *Brain Res* 81:325-331, 1974.
  57. Alexander MP: Disturbances in language initiation: Mutism and its lesser forms, in Joseph AR, Young RR (eds): *Movement Disorders in Neurology and Psychiatry*. Boston: Blackwell, 1992, pp 389-396.
  58. Fisher CM: Abulia minor vs. agitated behavior. *Clin Neurosurg* 31:9-31, 1985.
  59. Albert ML, Bachman DL, Morgan A, Helm-Estabrooks N: Pharmacotherapy for aphasia. *Neurology* 38:877-879, 1988.
  60. Saba L, Leiguarda R, Starkstein SE: An open-label trial of bromocriptine in nonfluent aphasia. *Neurology* 42:1637-1638, 1992.
  61. Alexander MP, Hiltbrunner B, Fischer R: The distributed anatomy of transcortical sensory aphasia. *Arch Neurol* 46:885-892, 1989.
  62. Warrington EK, Shallice T: Category-specific semantic impairment. *Brain* 107:829-854, 1984.
  63. Benson DF: Neurologic correlates of anomia, in Whitaker H, Whitaker HA (eds): *Studies in Neurolinguistics*. New York: Academic Press, 1979, pp 293-328.
  64. Berthier ML, Starkstein SE, Leiguarda R, et al: Transcortical aphasia. *Brain* 114:1409-1427, 1991.
  65. Feinberg TE, Dyckes-Berke D, Miner CR, Roane DM: Knowledge, implicit knowledge and meta-knowledge in visual agnosia and pure alexia. *Brain* 118:789-800, 1995.
  66. Feinberg TE, Rolhi LJG, Heilman KM: Multimodal agnosia after unilateral left hemisphere lesion. *Neurology* 36:864-867, 1986.
  67. Riddoch MJ, Humphreys GW, Coltheart M, Funnell E: Semantic systems or system? Neuropsychological evidence re-examined. *Cogn Neuropsychol* 5:3-25, 1988.
  68. Price BH, Gurvitz H, Weintraub S, et al: Neuropsychological patterns and language deficits in 20 consecutive cases of autopsy-confirmed Alzheimer's disease. *Arch Neurol* 50:931-937, 1993.
  69. Graff-Radford NR, Damasio AR, Hyman BT, et al: Progressive aphasia in a patient with Pick's disease. *Neurology* 40:620-626, 1990.
  70. Geschwind N, Quadfasel FA, Segarra JM: Isolation of the speech area. *Neuropsychologia* 6:327-340, 1968.
  71. McFarling D, Rothi LJ, Heilman KM: Transcortical aphasia from ischemic infarcts of the thalamus. *J Neurol Neurosurg Psychiatry* 45:107-112, 1982.
  72. Graff-Radford NR, Damasio H, Yamada T, et al: Nonhemorrhagic thalamic infarction. *Brain* 108:485-516, 1985.
  73. Cappa SF, Vignolo L: "Transcortical" features of aphasia following left thalamic hemorrhage. *Cortex* 19:227-241, 1979.
  74. Castro-Caldas A, Confraria A, Poppe P: Nonverbal disturbances in crossed aphasia. *Aphasiology* 1:403-413, 1987.
  75. Bryden MP, Hecaen H, DeAgostini M: Patterns of cerebral organization. *Brain Lang* 20:249-262, 1983.
  76. Annett M: *Left, Right, Hand and Brain: The Right Shift Theory*. Hillsdale, NJ: Erlbaum, 1985.

77. Alexander MP, Fischette MR, Fischer RS: Crossed aphasia can be mirror image or anomalous. *Brain* 112:953-973, 1989.
78. Basso A, Capitani E, Laiacoma M, Zanobio ME: Crossed aphasia: One or more syndromes? *Cortex* 1:25-45, 1985.
79. Alexander MP, Annett M: Crossed aphasia and related anomalies of cerebral organization: Case reports and a genetic hypothesis. *Brain Lang.* In press.
80. Trojano L, Balbi P, Russo O, Elefante R: Patterns of recovery in verbal and nonverbal function in a case of crossed aphasia. *Brain Lang* 46:637-661, 1994.
81. Fischer RS, Alexander MP, Gabriel C, et al: Reversed lateralization of cognitive functions in right handers. *Brain* 114:245-261, 1991.
82. Hecaen H, DeAgostini M, Monzon-Montes A: Cerebral organization in lefthanders. *Brain Lang* 12:261-284, 1981.
83. Basso A, Parabola M, Grassi MP, et al: Aphasia in left-handers. *Brain Lang* 38:233-252, 1990.
84. Naeser MA, Borod JC: Aphasia in lefthanders. *Neurology* 36:471-488, 1986.
85. Fuel M, Demonel JF, Cardebal I, et al: Aphasies sous-corticales: Etude neurolinguistique avec scanner x de 25 cas. *Rev Neurol* 140:695-710, 1984.
86. D'Esposito M, Alexander MP: Subcortical aphasia: Distinct profiles following left putaminal hemorrhages. *Neurology* 45:33-37, 1995.
87. DeRenzi E, Lucchelli F: Are semantic systems separately represented in the brain? The case of living category impairment. *Cortex* 30:3-25, 1994.
88. Smith S, Faust M, Beeman M, et al: A property level analysis of lexical semantic representation in Alzheimer's disease. *Brain Lang* 49:263-279, 1995.
89. Hodges JR, Salmon DP, Butters N: Semantic memory impairment in Alzheimer's disease: Failure of access or degraded knowledge? *Neuropsychologia* 30:301-314, 1992.
90. Tatemichi TK, Desmond DW, Prohovnik I, et al: Confusion and memory loss from capsular genu infarction: A thalamocortical disconnection syndrome? *Neurology* 42:1966-1979, 1992.
91. Weintraub S, Rubin NP, Mesulam MM: Primary progressive aphasia: Longitudinal course, neuropsychological profile and language features. *Arch Neurol* 47:1329-1335, 1990.
92. Hodges JR, Patterson K, Oxbury S, Funnell E: Semantic dementia. *Brain* 115:1783-1806, 1992.
93. Kertesz A, Hudson L, MacKenzie IRA, Munoz DG: The pathology and nosology of primary progressive aphasia. *Neurology* 44:2065-2072, 1994.
94. Mesulam MM: Slowly progressive aphasia without generalized dementia. *Ann Neurol* 11:592-598, 1982.